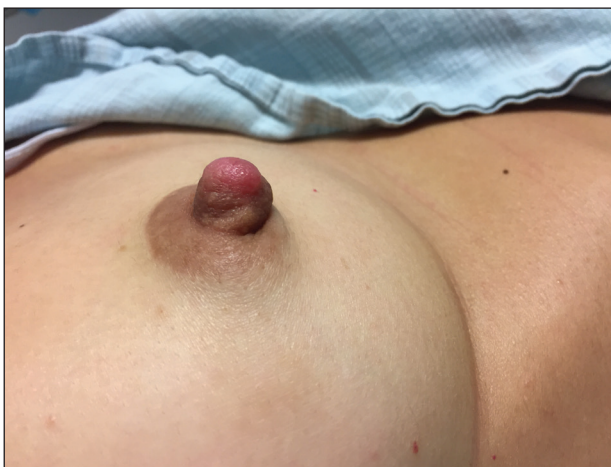

# Enlarging Nodule on the Nipple

Caren Waintraub, MD; Brianne Daniels, DO; Shari R. Lipner, MD, PhD

## Eligible for 1 MOC SA Credit From the ABD

This Photo Challenge in our print edition is eligible for 1 self-assessment credit for Maintenance of Certification from the American Board of Dermatology (ABD). After completing this activity, diplomates can visit the ABD website (<http://www.abderm.org>) to self-report the credits under the activity title "Cutis Photo Challenge." You may report the credit after each activity is completed or after accumulating multiple credits.



A healthy 48-year-old woman presented with a growth on the right nipple that had been slowly enlarging over the last few months. She initially noticed mild swelling in the area that persisted and formed a soft lump. She described mild pain with intermittent drainage but no bleeding. Her medical history was unremarkable, including a negative personal and family history of breast and skin cancer. She was taking no medications prior to development of the mass. She had no recent history of pregnancy or breastfeeding. A mammogram and breast ultrasound were not concerning for carcinoma. Physical examination showed a soft, exophytic, mildly tender, pink nodule on the

right nipple that measured 12×7 mm; no drainage, bleeding, or ulceration was present. The surrounding skin of the areola and breast demonstrated no clinical changes. The contralateral breast, areola, and nipple were unaffected. The patient had no appreciable axillary or cervical lymphadenopathy. A deep shave biopsy of the nodule was performed and sent for histopathologic examination.

## WHAT'S THE DIAGNOSIS?

- adenomyoepithelioma
- nipple adenoma (florid papillomatosis of the nipple)
- Paget disease of the breast
- subareolar sclerosing duct hyperplasia
- syringomatous adenoma

PLEASE TURN TO **PAGE 155** FOR THE DIAGNOSIS

From Weill Cornell Medicine, New York, New York. Drs. Waintraub and Lipner are from the Department of Dermatology, and Dr. Daniels is from the Department of Pathology.

The authors report no conflict of interest.

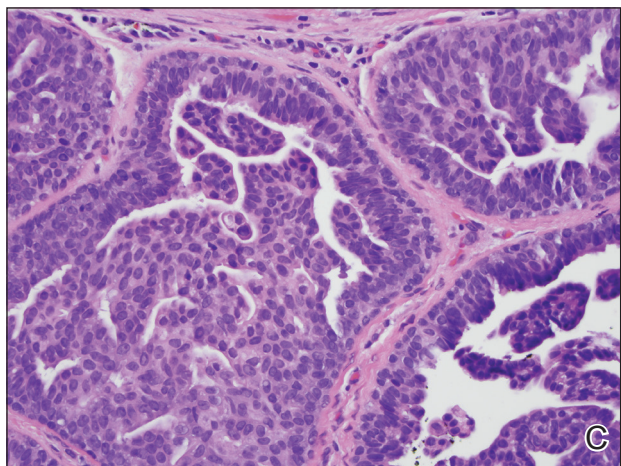
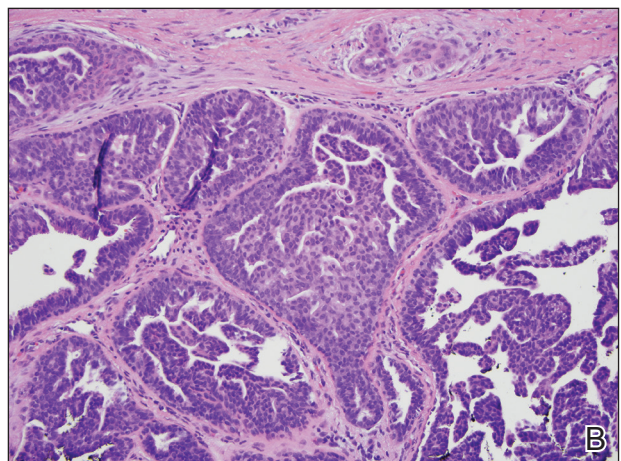
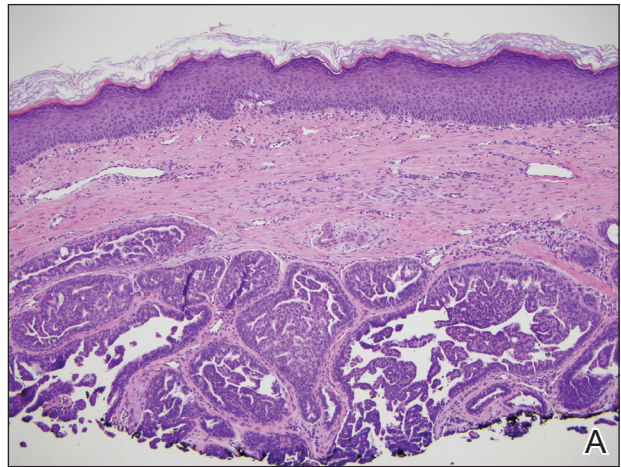
Correspondence: Shari R. Lipner, MD, PhD, 1305 York Ave, 9th Floor, New York, NY 10021 ([shl9032@med.cornell.edu](mailto:shl9032@med.cornell.edu)).

**THE DIAGNOSIS:****Nipple Adenoma (Florid Papillomatosis of the Nipple)**

**B**iopsy of the nodule showed florid papillary hyperplasia of the ductal epithelium within the dermis that was sharply demarcated from the background stroma (Figure, A and B). Neither cytological nor architectural atypia were evident. There was no notable necrosis (Figure C). There was a background of fibrosis whereby the glandular ductal structures assumed a somewhat irregular growth pattern within the dermis with attendant hemorrhage. The patient underwent complete excision of the lesion. No evidence of carcinoma was seen on the final pathology, and the final margins were negative.

First described in 1923 and fully characterized in 1955, nipple adenoma (also known as florid papillomatosis of the nipple) is a benign proliferative neoplasm that originates in the lactiferous ducts of the nipple.<sup>1,2</sup> It most commonly affects women aged 40 to 50 years (range, 0–89 years); less than 5% of cases are reported in men.<sup>3,4</sup> It predominantly is unilateral, with only rare cases of bilateral papillomatosis reported. Patients often present with serous or serosanguineous discharge and an itching or burning sensation. Symptoms may worsen with the menstrual cycle.<sup>4</sup> On physical examination, it presents as an ill-defined red nodule on the nipple with crusting, erosion, or erythema of the nipple surface. Although imaging generally is not used to confirm the diagnosis, mammography should be performed prior to biopsy to rule out underlying breast pathology. Dermoscopy may show linear cherry red structures or red serpiginous and annular structures.<sup>5,6</sup> The differential diagnosis of nipple adenoma includes Paget disease of the breast, adenomyoepithelioma, subareolar subsclerosing duct hyperplasia, syringomatous adenoma, adenosis tumor, low-grade adenosquamous carcinoma, low-grade ductal carcinoma in situ, tubular carcinoma, and sweat gland tumors.<sup>3</sup>

Microscopic features of nipple adenoma have been categorized into 4 subtypes: sclerosing papillomatosis, papillomatosis, adenosis, and a mixed pattern.<sup>3,7</sup> The tumors may have keratin cysts and focal necrosis but no atypia, and the myoepithelial cell layer is retained. Nipple adenomas show a glandular proliferation in the dermis that is relatively well circumscribed with glands that vary in appearance between a simple adenosislike pattern of growth to a papillary hyperplasia and/or usual ductal hyperplasia growth pattern. A pseudoinfiltrative pattern can occur when the glandular epithelium is entrapped within stromal fibrosis; however, the myoepithelial layer is retained. Occasionally, the glandular epithelium can grow in continuity with the surface squamous epithelium of the nipple, clinically simulating Paget disease of the breast.<sup>8</sup> Immunohistochemical stains, specifically p63, p40, calponin 1, h-caldesmon, cytokeratin 5/6, CD10, and



Nipple adenoma. A, Proliferation of ducts within the dermis (H&E, original magnification  $\times 10$ ). B, Ducts are lined by papillary epithelium (H&E, original magnification  $\times 20$ ). C, Bland cytology and lack of concerning features such as necrosis (H&E, original magnification  $\times 40$ ).

$\alpha$  smooth muscle actin, highlight the myoepithelial cells, while cytokeratin 7 identifies the ductal epithelium, supporting the diagnosis.<sup>6</sup> In addition to biopsy and microscopic tissue examination, touch preparation cytology, curettage cytology, and fine needle aspiration techniques have been used to perform cytologic examination of the lesions, aiding in identification of the benign or malignant nature of the neoplasm.<sup>6</sup> Nipple adenoma also is referred to as florid papillomatosis of the nipple, papillary adenoma, erosive adenomatosis, and subareolar duct papillomatosis.<sup>7</sup>

Although nipple adenoma is a benign tumor, up to 16.5% of affected patients had an ipsilateral or contralateral mammary carcinoma.<sup>9</sup> The majority arose coincidentally but separately in the same breast, and carcinoma arose directly from the nipple adenoma in 8 cases; 3 cases were carcinomas that arose in men.<sup>10</sup> A definitive association or causal relationship between nipple adenoma and subsequent development of breast cancer has not been identified, and the incidence of nipple adenoma in patients with a positive family history of breast cancer has not been examined. Therefore, although various treatments including cryosurgery, nipple splitting enucleation, and Mohs micrographic surgery have been proposed, complete excision remains the gold standard of therapy.

Regular breast examinations and digital mammography are necessary to screen for local recurrences.

#### REFERENCES

1. Miller E, Lewis D. The significance of serohemorrhagic or hemorrhagic discharge from the nipple. *JAMA*. 1923;81:1651-1657.
2. Jones DB. Florid papillomatosis of the nipple ducts. *Cancer*. 1955;8:315-319.
3. Rosen PP. *Rosen's Breast Pathology*. 3rd ed. Philadelphia, PA: Lippincott Williams & Wilkins; 2009:120-128.
4. Brownstein MH, Phelps RG, Maqin PH. Papillary adenoma of the nipple: analysis of fifteen new cases. *J Am Acad Dermatol*. 1985;12:707-715.
5. Takashima S, Fujita Y, Miyauchi T, et al. Dermoscopic observation in adenoma of the nipple. *J Dermatol*. 2015;42:341-342.
6. Spohn G, Trotter S, Tozbikian G, et al. Nipple adenoma in a female patient presenting with persistent erythema of the right nipple skin: case report, review of the literature, clinical implications, and relevancy to health care providers who evaluate and treat patients with dermatologic conditions of the breast skin. *BMC Dermatol*. 2016;16:4.
7. Shin SJ. Nipple adenoma (florid papillomatosis of the nipple). In: Dabbs DJ, ed. *Breast Pathology*. Philadelphia, PA: Elsevier Saunders; 2012:286-292.
8. Schnitt SJ, Collins LC. *Biopsy Interpretation of the Breast*. 2nd ed. Philadelphia, PA: Wolters Kluwer Health/Lippincott Williams & Wilkins; 2013.
9. Salemis NS. Florid papillomatosis of the nipple: a rare presentation and review of the literature. *Breast Dis*. 2015;35:153-156.
10. Di Bonito M, Cantile M, Collina F, et al. Adenoma of the nipple: a clinicopathological report of 13 cases. *Oncol Lett*. 2014;7:1839-1842.